KJSB

Korean Journal of Sport Biomechanics 2018; 28(1): 55-60
http://dx.doi.org/10.5103/KJSB.2018.28.1.55
http://e-kjsb.org eISSN 2093-9752

ORIGINAL

The Effects of Computer Game Exposure on Musculoskeletal Pathological Symptoms in Adolescents

Woen-Sik Chae, Jae-Hu Jung

Department of Physical Education, Kyungpook National University, Daegu, South Korea

Received : 29 January 2018
Revised : 10 March 2018
Accepted : 20 March 2018

Corresponding Author
Jae-Hu Jung
Department of Physical Education, Kyungpook National University, 80 Daehak-ro, Buk-gu, Daegu, 41566, South Korea
Tel : +82-53-950-7462
Fax : +82-53-955-4235
Email : jjhjjh81@naver.com

Objective: This study aimed to analyze the effects of computer game exposure on pathological musculoskeletal symptoms in adolescents.

Method: This study included 10 male junior high school students who used computers less than 3 times a week for 1 hr per day. The subjects were asked to play computer games for 4 hr. Magnetic resonance imaging of the hand and wrist, from the distal radius and ulnar head to the distal phalanges, and radiography of the cervical vertebrae were performed before and after playing computer games. For each dependent variable, a paired *t*-test was performed to identify significant changes before and after a 4-hr active computer game ($p<.05$).

Results: The horizontal diameters of the flexor tendons in the index and middle fingers were significantly reduced after playing computer games. The horizontal diameters of the flexor tendons of other fingers did not show any significant differences, but there was a tendency toward a decrease after playing computer games. There was no significant change in the cervical lordosis angle before and after playing computer games. However, the cervical lordosis angle was relatively decreased.

Conclusion: The results of this study showed that computer game exposure had direct and indirect effects on morphological changes of flexor tendons. In addition, playing computer games for long periods of time can have a negative effect on normal functioning of the musculoskeletal system, with the possible development of abnormalities. However, computer game exposure in adolescents cannot be decisively identified as a factor causing pathological symptoms, based on the results of this study alone. Thus, long-term longitudinal studies on the overall musculoskeletal system are necessary.

Keywords: Computer game, Pathological symptom, MRI, X-ray, Finger, Cervical vertebrae

INTRODUCTION

With recent developments in information technology, various digital devices have become widely used, with increasing frequency. Since these devices increase job efficiency and productivity, provide information quickly, and are convenient, they have become necessary in daily life. However, with increasing dependence on digital devices, the time spent in their use is rapidly increasing, acting as a major cause of societal problems, including various forms of addiction and digital dementia.

Addiction to computer gaming is a major societal problem associated with the use of digital devices. Computer gaming leads to addiction if it exceeds a certain appropriate level of use and can result in individual and crime-related problems, including difficulties in daily life, psychological difficulties, musculoskeletal difficulties, compulsive use, withdrawal symptoms, tolerance, and difficulties discerning reality (Lee & Ahn, 2002; Han & Lee, 2006). In particular, addiction to computer gaming exerts negative influences on the body and mind of adolescents, and the use of and addiction to computer gaming have reached dangerous levels among adolescents. Moreover, individual and social problems caused by adolescent addiction to computer gaming have become serious problems worldwide (Lee & Sim, 2010). According to the Korean Societal Trends 2017 recently reported by Statistics Korea, 91.1% of upper year students in primary schools (grades 4~6), 82.5% of junior high school students, and 64.2% of high school students play games, and 2.5% of all have been reported to be addicted to gaming. According to a survey conducted in 2016 by the Ministry of Gender Equality and Family, the proportion of the addiction risk group, a group preceding the gaming addiction group, has increased consistently. As such, computer gaming has become a leisure activity for adolescents. However, since it is often perceived as an individual and societal problem interfering with daily lives of adolescents, many studies investigating addiction to computer gaming have been widely conducted.

According to multiple previous studies on addiction or overindulgence in computer gaming, Kim (2011) who compared the brains of normal adolescents and those addicted to gaming through functional magnetic resonance imaging (fMRI) reported that the areas concerning

Copyright © 2018 Korean Journal of Sport Biomechanics
This is an Open Access article distributed under the terms of the Creative Commons Attribution Non-Commercial License (http://creativecommons.org/licenses/by-nc/3.0/) which permits unrestricted noncommercial use, distribution, and reproduction in any medium, provided the original work is properly cited.

disembodiment, which is a phenomenon in which ego leaves the boundaries of the body, are activated in adolescents addicted to gaming. Voluse, Körkel and Sobell (2007) reported that most adolescents tend to perceive their ego differently in online and offline situations. Hong (2002) reported that adolescents addicted to gaming have diminished functioning of the frontal lobe of the brain, which is responsible for judgment and emotional control, in comparison to the normal control group, and thus have problems in judgment and emotional control.

Physical symptoms caused by addiction to computer gaming include excessive stiffening of shoulder or neck muscles and back pain (Kim & Chae, 2012; Shim, 2001). If such symptoms continue, they can develop into scoliosis in which the spine bends in an abnormal manner (Kim, 2012; Moon et al., 2014; Park et al., 2012). Gerr, Monteilh and Marcus (2006) reported that prolonged use of computers can cause problems in the upper limb musculoskeletal system, including the neck, shoulders, hands, and wrists. Cho, Lee and Choi (2008) reported an electromyogram study on prolonged use of computers and neck and shoulder muscles and stated that turtle neck syndrome patients have decreased muscle activity and increased muscle fatigue in the neck and back. Armstrong (1986) and Louis (1987) suggested that excessive repeated movement, excessive force, and inappropriate posture caused by computer use can lead to carpal tunnel syndrome.

As such, with increasing use and frequency of use of computers as well as increasing scope of use of computers, more patients are being diagnosed with visual display terminal syndrome, which comprises health-related problems associated with computer use, and negative aspects of computer use are being emphasized. Visual display terminal syndrome is often caused by continued repetitive use of the arms, hands, and fingers and by static posture during computer use and can lead to cumulative trauma disorders syndrome which can result in chronic diseases in the musculoskeletal system. Such cumulative trauma disorders syndrome causes symptoms in muscles, ligaments, and nerves; in particular, as in turtle neck syndrome and carpal tunnel syndrome, it causes severe pain in fingers, wrists, and neck (World Health Organization, 1987). Therefore, pathological studies on neck and hands, which are body parts that are often affected by prolonged use of computers, are necessary.

Most previous studies have been limited to analyzing psychological symptoms and phenomena in adolescents caused by computer gaming, and only a few pathological studies have investigated the possibility of musculoskeletal diseases. Moreover, since previous studies do not suggest objective indices of pathological changes of the musculoskeletal system caused by computer gaming, systematic research and investigation of problems that can be caused by adolescent exposure to computer gaming are necessary.

Therefore, the present study aims to analyze how computer game exposure influences pathological musculoskeletal symptoms in adolescents. Through this study, we seek to understand pathological musculoskeletal symptoms in adolescents that can be caused by computer gaming and to find ways to decrease such problems.

METHODS

1. Participants

In order to investigate the influence of exposure to computer gaming on pathological musculoskeletal symptoms in adolescents, 10 male junior high school students who use computers for less than 1 hour a day and less than 3 times a week were selected. The participants were 15.7±0.7 y old, 171.7±5.5 cm tall, and weighed 60.0±6.8 kg. Before the experiments, the purpose and methods of the study were explained in detail to the participants. The methods of this study were reviewed by the institutional review board (IRB) of ** University before the experiments. The participants and their guardians learned about the purpose and details of the study through the explanation sheet and consent form approved by the IRB and consented to participate in the study.

2. Experimental setup

1) MRI

In order to analyze pathological changes in wrist joints caused by computer gaming, MRI tests were conducted. For the MRI test, 2 1.5 T MRI scanners (Magnetom Avanto SQ, Siemens, Germany) were used, and small-size flex coils were used (Figure 1).

Figure 1. MRI used in this study

2) X-ray

In order to evaluate cervical lordosis, an X-ray scanner (XGE0 GC80, Samsung Medicine, Korea) was used to image the lateral view of the cervical vertebrae (Figure 2).

3. Data collection

A computer game (Sudden Attack) that can cause fatigue in the participants' hands, wrists, and neck was chosen. The 10 participants played the game for 4 h, and MRI of the wrists and X-ray of the cervical

Figure 2. X-ray used in this study

spine were conducted twice, before and after gaming. MRI scans of the hands and the wrists, from the distal radius and ulnar head to proximal phalanges, were taken using the coronal T2 gradient 3D technique (TR 45 ms, TE 25 ms, 0.6-mm slice thickness). Cervical spine X-rays were taken for a lateral view of the neck, and the participants were asked to close their eyes and relax their neck, shoulder, and arm muscles as much as possible while their proximal fibula and occipital bone were aligned horizontally. They were also asked to assume the most comfortable and natural posture possible.

4. Data analysis

1) MRI

In the MR images collected before and after computer gaming, the horizontal diameter of the flexor tendon in the index finger (HDFTI), vertical diameter of the flexor tendon in the index finger (VDFTI), horizontal diameter of the flexor tendon in the middle finger (HDFTM), and vertical diameter of the flexor tendon in the middle finger (VDFTM) were measured. The diameter of the flexor tendon was analyzed with the TeraRecon (TeraRecon Inc., USA) software from volume data acquired through thin-slice scans, and the diameter at the longest region was measured horizontally and vertically on axial scans. Measurements were made at a total of 3 levels: level 1 at the ulnar head, level 2 at the carpometacarpal joint, and level 3 at the metacarpophalangeal joint. Moreover, the diameter of the flexor tendon was measured at the same angle and location before and after computer gaming using the slope of the bone as the index in coronal, sagittal, and axial scans of each level (Bonél et al., 2001; Uchiyama et al., 2005; Radack, Schweitzer & Taras, 1997). Two radiologists participated in data analysis (Figure 3).

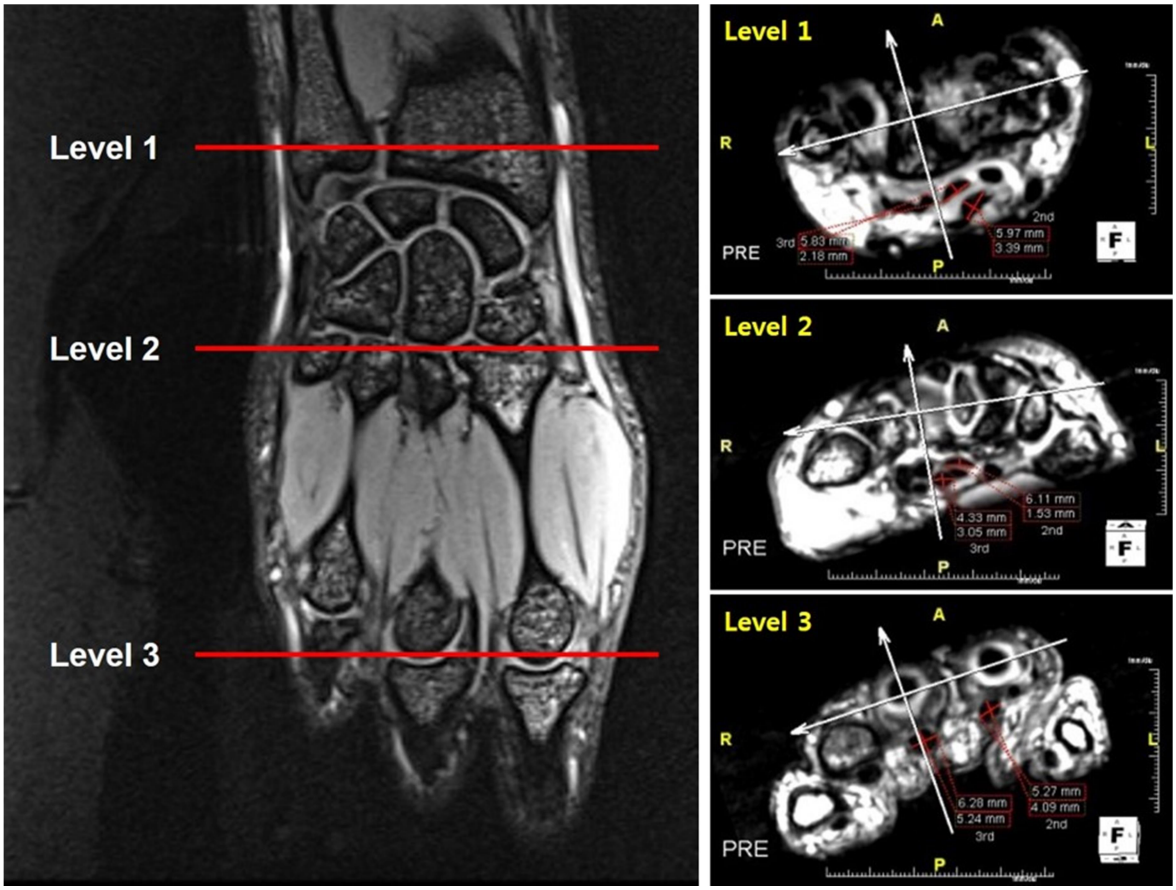

Figure 3. Diameters of flexor tendons in the index and middle fingers

2) X-rays

To measure cervical lordosis using X-rays, the Cobb angle, which is formed by a line perpendicular to the line connecting the anterior nodule (C1) of the atlas and the middle of the posterior nodule and a line tangent to the inferior border of C7 center, was measured using cervical spine X-rays (lateral view) (Figure 4). If the angle between C1 and C7 was between 35 and 45°, the participants were classified as having normal lordosis. If the angle was less than 35°, the participants were classified as having decreased lordosis. When the angle was greater than 45°, the participants were classified as having extreme lordosis (Harrison, Harrison, Troyanovich and Harmon, 2000).

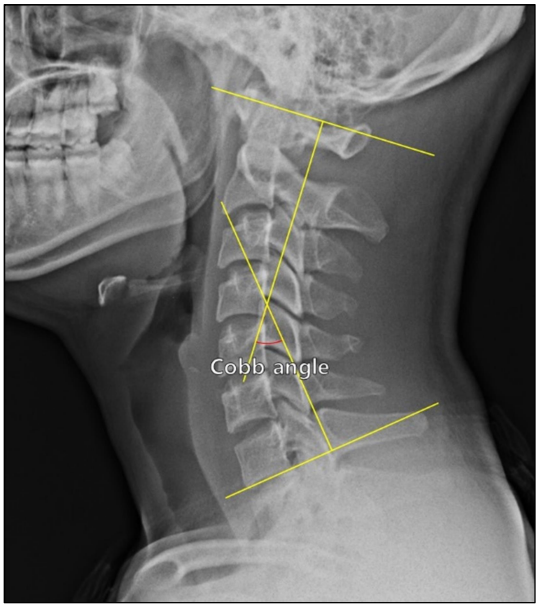

Figure 4. Cobb angle used in this study

5. Statistical analysis

To test the statistical significance of MRI and X-ray tests conducted before and after computer gaming, paired *t*-tests were conducted at a significance level of $p<.05$ using SPSS 23.0.

RESULTS

1. MRI

In terms of the changes in the diameter of the flexor tendon of fingers before and after computer gaming, HDFTI and HDFTM decreased significantly after gaming. Moreover, although no statistically significant difference was observed in the diameters of the flexor tendons in other fingers, the diameters still tended to show a decrease after gaming (Table 1~3).

Table 1. Diameter of flexor tendons at level 1 (mm)

	pre	post	*t*-value	*p*-value
HDFTI	5.62±1.27*	5.00±0.77*	2.354	.043
VDFTI	2.89±1.43	3.03±1.35	-.945	.370
HDFTM	5.23±0.78*	4.70±0.57*	2.517	.033
VDFTM	2.68±1.02	2.65±1.19	.264	.798

Note. *significant difference between pre and post tests at $p<.05$.

Table 2. Diameter of flexor tendons at level 2 (mm)

	pre	post	*t*-value	*p*-value
HDFTI	5.16±1.09	4.92±0.90	1.108	.296
VDFTI	1.83±0.29	1.69±0.28	1.744	.115
HDFTM	4.16±0.60	3.91±0.63	1.164	.274
VDFTM	2.95±0.53	2.95±0.50	0.000	1.000

Table 3. The diameter of the flexor tendons at level 3 (mm)

	pre	post	*t*-value	*p*-value
HDFTI	5.78±0.68	5.59±0.71	.985	.351
VDFTI	3.73±0.67	3.99±0.57	-1.009	.339
HDFTM	7.11±0.91	6.93±0.36	.574	.580
VDFTM	4.87±0.70	4.84±0.82	.167	.871

2. X-ray

No statistically significant difference was observed in the cervical lordosis angle before and after computer gaming. However, the cervical lordosis angle was relatively decreased after gaming; under both conditions, the Cobb angle was less than 35°, corresponding to the decreased lordosis group (Table 4).

Table 4. Cobb angle (deg)

	pre	post	*t*-value	*p*-value
Cobb angle	33.4±9.2	32.7±10.2	.318	.758

DISCUSSION

Gupta and Mahalanabis (2006) investigated hand function, and reported that gripping, repeated pushing, and typing, which are repetitive movements in the hands and wrists during use of a mouse, can cause carpal tunnel syndrome. Based on such findings, the present study aimed to investigate morphological changes in the carpal tunnel

caused by computer gaming through MRI of the hands and wrists.

According to the MRI tests conducted in this study, HDFTI and HDFTM of the ulnar head decreased significantly after gaming. Lee et al. (2002) applied MRI tests in treating carpal tunnel syndrome, and reported that repeated movements of the wrists increase the pressure within the carpal tunnel, which is a very narrow space formed by hand bones and fibrous tissue as well as a closed space through which 9 flexor tendons and the median nerve run. Jang (1998) analyzed the movement of the wrist joints during computer use and reported that ulnar flexing of the wrists is often observed during the use of a mouse. Since such posture increases static muscle load in the wrists, the author reported that repeated movements can cause cumulative trauma disorders syndrome in which chronic diseases arise in body cartilage. The present findings are contradictory to previous findings, although we found morphological changes in the finger flexor tendons since repeated use of a mouse led to decreases in HDFTI and HDFTM in the carpal tunnel within the wrists. Guggenberger et al. (2012) and Monagle et al. (1999) reported that different locations along the median nerve from its entry and movement through the carpal tunnel can cause different degrees of flattening of the median nerve; in particular, the median nerve was reported to be flattened within the carpal tunnel whereas edema was observed before the median nerve entered the carpal tunnel. Considering such findings, the diameter of the finger flexor tendons, which flatten the median nerve by increasing the intra-carpal-tunnel pressure at the beginning of the carpal tunnel at the ulnar bone, seems to decrease temporarily. Although the findings of the present study do not conclude that the flexor tendons of the fingers exert direct influences in increasing the intra-carpal-tunnel pressure, it is still possible that minute morphological changes of the flexor tendons of the fingers can lead to pathological musculoskeletal changes.

X-ray tests showed no significant difference in cervical lordosis angle before and after gaming. However, as the Cobb angle, which can be used to evaluate cervical lordosis in adolescents, was less than 35° before and after gaming in all participants, all were classified as having decreased lordosis. Lim et al. (2015) reported that loss of cervical lordosis can lead to various degenerative changes since the cervical vertebrae directly support the weight of the head. Cho et al. (2008) reported that using computers for long periods of time with decreased cervical lordosis angles as in forward head posture can lead to excessive tension and imbalance of surrounding muscles in the neck and back that support the cervical vertebrae. This can lead to muscular tension, fatigue, and pain. As seen in previous findings, adolescent cervical lordosis angles outside the normal range are expected to negatively influence their musculoskeletal system. However, since the cervical lordosis angle in adolescents did not differ greatly before and after gaming in this study, it is difficult to judge changes in cervical lordosis angle caused by computer gaming. In other words, the adolescents seem to have had decreased cervical lordosis angles since they have been using computers and other digital devices for long periods of time in their daily lives. Moreover, in the present study, the individual differences in cervical lordosis could not be taken into consideration due to the difficulties of selecting male junior high school students with limited hours of use of computers. It would thus be necessary for future studies to analyze normal participants with similar cervical lordosis angles.

CONCLUSION

The present study performed MRI of the hands and wrists and X-rays of the neck to comparatively analyze pathological musculoskeletal changes in adolescents after computer gaming. Computer gaming exposure was found to directly and indirectly influence morphological changes in the finger flexor tendons. Moreover, we also confirmed that playing games for long periods of time can negatively influence the normal functioning of the human musculoskeletal system and can lead to pathological symptoms. However, since it is difficult to draw conclusions on the causes of pathological musculoskeletal symptoms seen after computer gaming exposure in adolescents, future studies would be required in this regard. Therefore, future long-term longitudinal studies would need to evaluate the overall musculoskeletal system to confirm changes in pathological symptoms caused by computer gaming exposure and also to confirm their causes.

ACKNOWLEDGEMENTS

This work was supported by the National Research Foundation of Korea Grant funded by the Korean Government (NRF-2014S1A5A2A-01011961).

REFERENCES

Armstrong, T. J. (1986). Ergonomics and cumulative trauma disorders. *Hand Clinics*, *2*(3), 553-565.

Bonél, H. M., Heuck, A., Frei, K. A., Herrmann, K., Scheidler, J., Srivastav, S. & Reiser, M. (2001). Carpal tunnel syndrome: assessment by turbo spin echo, spin echo, and magnetization transfer imaging applied in a low-field MR system. *Journal of Computer Assisted Tomography*, *25*(1), 137-145.

Cho, W. H., Lee, W. Y. & Choi, H. K. (2008). *An investigation on the biomechanical effects of turtle neck syndrome through EMG Analysis*. Proceedings of the 2008 conference of korean society for precision engineering, 195-196.

Gerr, F., Monteilh, C. P. & Marcus, M. (2006). Keyboard use and musculoskeletal outcomes among computer users. *Journal of Occupational Rehabilitation*, *16*(3), 265-277.

Guggenberger, R., Markovic, D., Eppenberger, P., Chhabra, A., Schiller, A., Nanz, D., Prussmann, K. & Andreisek, G. (2012). Assessment of median nerve with MR neurography by using diffusion-tensor imaging: normative and pathologic diffusion values. *Radiology*, *265*(1), 194-203.

Gupta, A. D. & Mahalanabis, D. (2006). Study of hand function in a group of shoe factory workers engaged in repetitive work. *Journal of Occupational Rehabilitation*, *16*(4), 675-684.

Han, S. A. & Lee, H. M. (2006). Concern with online game addiction and juvenile delinquency. *Korea Association of Criminal Psychology*, *2*(1), 229-244.

Harrison, D. E., Harrison, D. D., Troyanovich, S. J. & Harmon, S. (2000).

A normal spinal position: it's time to accept the evidence. *Journal of Manipulative & Physiological Therapeutics*, *23*(9), 623-644.

Hong, M. J. (2002). *Computer-related working environments and musculoskeletal symptoms in the white collar workers*. Unpublished Master's Thesis. Graduate School of Yonsei University.

Jang, M. Y. (1998). *The effect of computer mouse position and forearm support on muscular load*. Unpublished Master's Thesis. Graduate School of Yonsei University.

Kim, D. S. & Chae, W. S. (2012). Biomechanical analysis of a smartphone task with different postures. *Korean Journal of Sport Biomechanics*, *22*(2), 253-259.

Kim, J. S. (2012). *A Study on the Design Development of Ergonomical Mouse*. Unpublished Master's Thesis. Graduate School of Kookmin University.

Kim, Y. R. (2011). *fMRI Study of Disembodiment in Internet Overuse Adolescents*. Unpublished Doctor's Dissertation. Graduate School of Chungbuk National University.

Lee, H. C. & Ahn, C. Y. (2002). Development of the internet game addiction diagnostic scale. *Korean Journal of Health Psychology*, *7*(2), 211-239.

Lee, J. M. & Sim, J. W. (2010). Effects of computer game addiction in children. *The Korean Society for Computer Game*, *23*(2), 237-245.

Lee, K. Y., Lee, Y. J., Kim, S. H., Song, H. G. & Kim, J. (2002). MR imaging of carpal tunnel syndrome: The usefulness of MRI in treatment decisions. *Journal of the Korean Society for Clinical Neurophysiology*, *4*(2), 114-118.

Lim, J. S., Yoon, K. H., Lee, S., Cho, Y. E., Park, J. M., Lee, S. H. & Kim, Y. S. (2015). An analysis of the state of cervical disc herniation according to cervical lordosis and age. *The Acupuncture*, *32*(3), 107-115.

Louis, D. S. (1987). Cumulative trauma disorders. *The Journal of Hand Surgery*, *12*(5), 823-825.

Monagle, K., Dai, G., Chu, A., Burnham, R. S. & Snyder, R. E. (1999). Quantitative MR imaging of carpal tunnel syndrome. *American Journal of Roentgenology*, *172*(6), 1581-1586.

Moon, H. H., Jung, S. Y., Park, S. S., Kim, B. K. & Park, Y. J. (2014). The effect of corrective exercise on cobb's angle, static and dynamic foot pressure of patients with kyphosis. *Korean Journal of Sport Biomechanics*, *24*(2), 103-109.

Park, Y. S., Woo, B. H., Kim, J. M. & Lim, Y. T. (2012). Development of Wearing of Musculo-Skeletal Functional Garment for Adolescents' Idiopathic Scoliosis. *Korean Journal of Sport Biomechanics*, *22*(3), 365-371.

Radack, D. M., Schweitzer, M. E. & Taras, J. (1997). Carpal tunnel syndrome: are the MR findings a result of population selection bias?. *American Journal of Roentgenology*, *169*(6), 1649-1653.

Shim, H. T. (2001). *A study on the effectiveness of wristbands for mouse user*. Unpublished Master's Thesis. Graduate School of Hongik University.

Uchiyama, S., Itsubo, T., Yasutomi, T., Nakagawa, H., Kamimura, M. & Kato, H. (2005). Quantitative MRI of the wrist and nerve conduction studies in patients with idiopathic carpal tunnel syndrome. *Journal of Neurology, Neurosurgery & Psychiatry*, *76*(8), 1103-1108.

Voluse, A., Körkel, J. & Sobell, L. C. (2007). *Self-change toolbox: Tools, tips, websites, and other informational resources for assessing and promoting self-change*. Promoting self-change from addictive behaviors: Practical implications for policy, prevention, and treatment, 239-255.

World Health Organization. (1987). Visual display terminals and workers' health.